

NEW GUIDELINES

A Guideline Protocol for the Assessment of the Mitral Valve With a View to Repair From the British Society of Echocardiography Education Committee

Richard Steeds, Chair, Bushra Rana (Lead Author),

Jane Allen, John Chambers, Richard Jones, Guy Lloyd, Nicola Smith, Julie Sandoval, Gill Wharton

1. Introduction

1.1 The BSE Education Committee has previously published a minimum dataset for a standard adult transthoracic echocardiogram, available on-line at www.bsecho.org. This document specifically states that the minimum dataset is usually only sufficient when the echocardiographic study is entirely normal. The aim of the Education Committee is to publish a series of appendices to cover specific pathologies to support this minimum dataset.

1.2 The intended benefits of such supplementary recommendations are to:

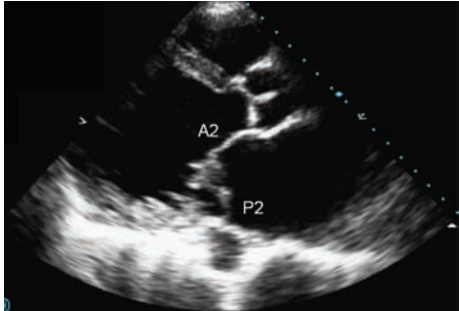
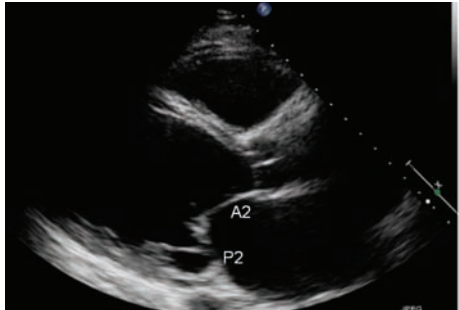
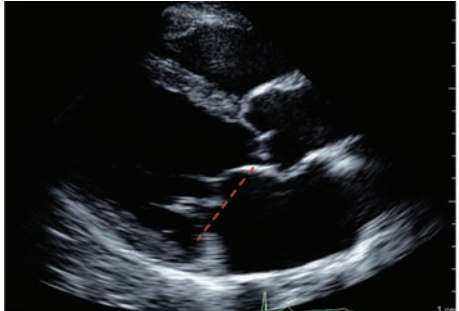
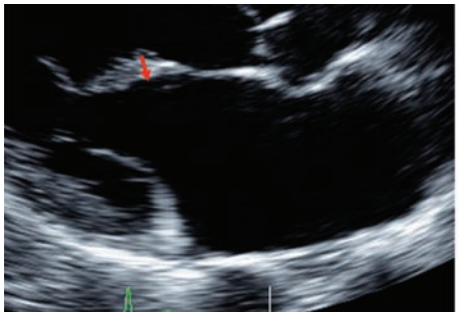
- Support cardiologists and echocardiographers to develop local protocols and quality control programs for adult transthoracic study
- Promote quality by defining a set of descriptive terms and measurements, in conjunction with a systematic approach to performing and reporting a study in specific disease-states
- Facilitate the accurate comparison of serial echocardiograms performed in patients at the same or different sites.

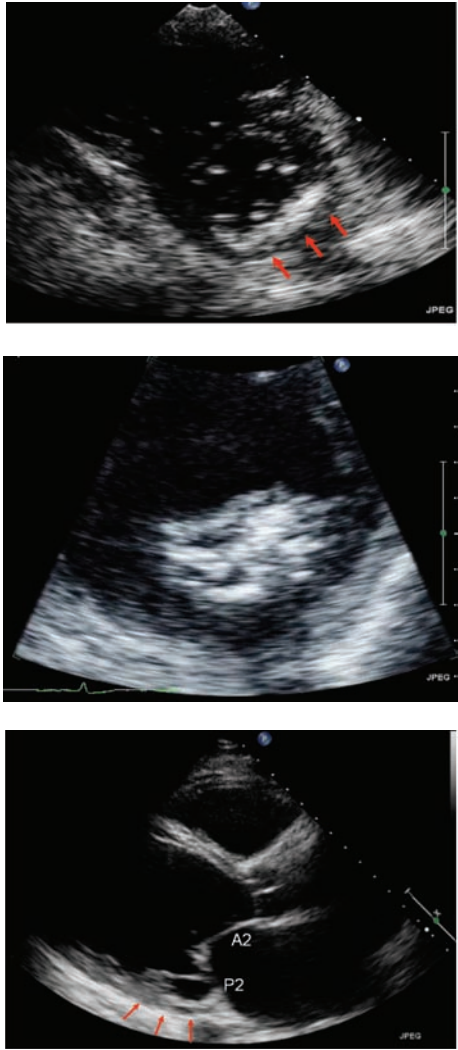
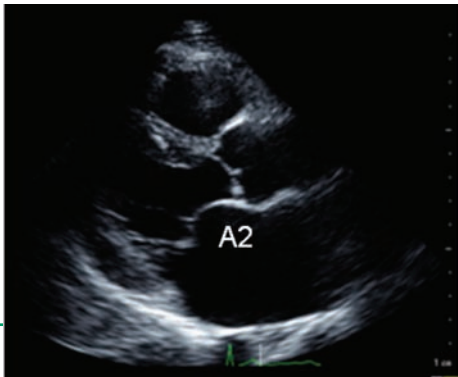
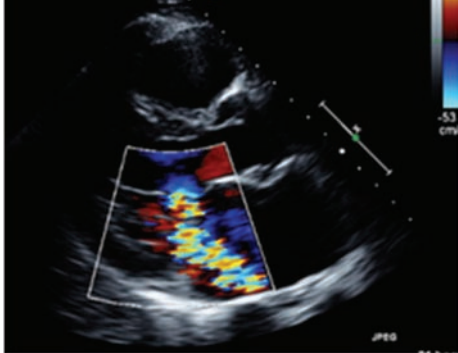
1.3. This document gives recommendations for the image and analysis dataset required in patients being assessed for mitral regurgitation with a view to suitability for repair. This is of particular importance given the improvement in life expectancy and quality of life of patients undergoing successful mitral valve repair compared to those who have an operation to replace their mitral valve. The views and measurements are supplementary to those outlined in the minimum dataset and are given assuming a full study will be performed in all patients.

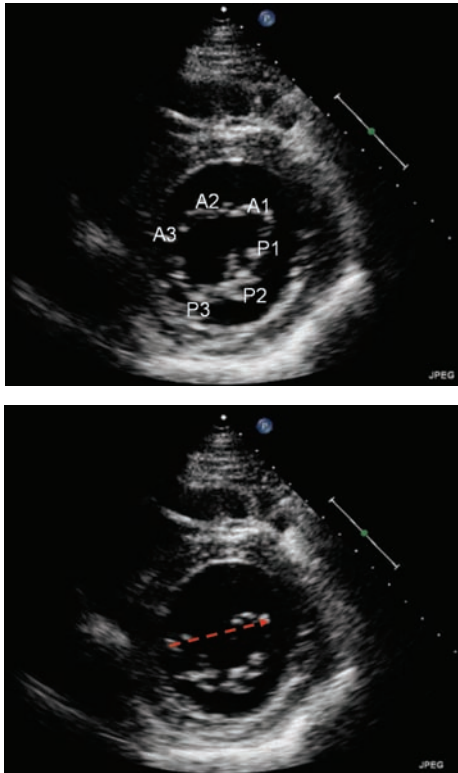
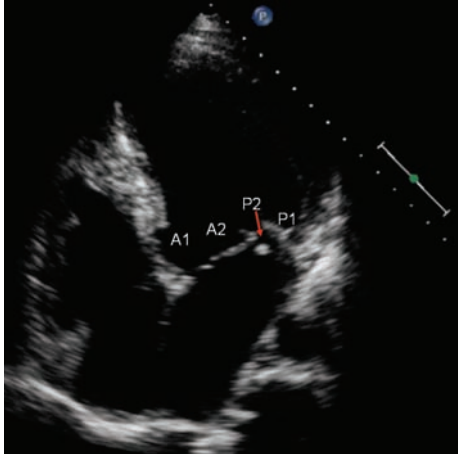
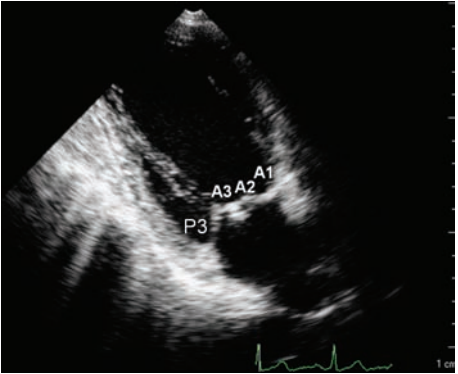
1.4 When the condition or acoustic windows of the patient prevent the acquisition of one or more components of the supplementary Dataset, or when measurements result in misleading information (e.g. off-axis measurements) this should be stated.

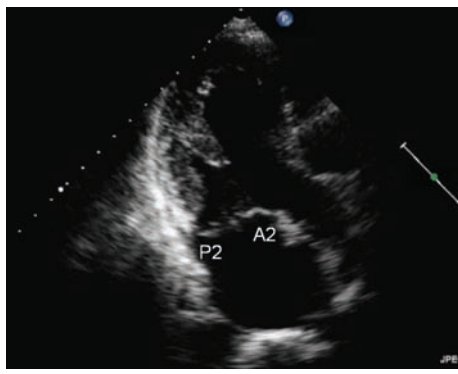
1.5 This document is a guideline for echocardiography in the assessment of the mitral valve with a view to repair and will be updated in accordance with changes directed by publications or changes in practice.

Assessment of the LV

View	Modality	Measurements	Explanatory Note	Image
PLAX	2D	Segments viewed¹	A2/P2	   
		Leaflet motion² :normal	Morphologically normal leaflet appearance; coaptation failure or leaflet perforation	
		:excessive	During systole, leaflet billowing into LA, beyond plane of mitral annulus >2mm (prolapse)	
		:restriction ³	Leaflet pulled below annulus level with restriction in systole alone (type 3A), coaptation depth < 10mm (end systole, distance from point where leaflets coapt to plane of annulus ³ or in systole and diastole (type 3B, usually Rheumatic disease).	
	Annulus measurement⁴	AP diameter (short axis) End systole 29mm±3.5mm End diastole 33mm±3.2mm		
	Leaflet thickness⁵	diastole, zoom mode: normal thickness <5mm comment on integrity of leaflet		
	Colour Doppler	Calcification⁶ :Annulus Ca2+ score :leaflets and subvalve	Annulus scoring system ⁶ (0-5: P1,P2,P3,AMVL, Commissures) Note: location and extent Leaflet- free edge, body, near insertion Subvalve-chords, PM	

		<p>LV wall motion abnormalities</p> <p>MR jet direction</p>	<p>LV geometry affecting subvalvular anatomy, usually restrictive leaflet motion (type3A)</p> <p>Contralateral to side of prolapse (ie PMVL prolapse=anteriorly directed jet) Ipsilateral to site of restriction (ie PMVL restriction=posteriorly directed jet) Central in central coaptation failure 'Complex' jet in multiple lesions</p>	
<p>Modified PLAX Toward AV</p> <p>Sweep (scout) through valve segments</p>	<p>2D</p> <p>Colour Doppler</p>	<p>Segments viewed</p> <p>Leaflet motion Leaflet thickness Calcification LV wall motion abnormalities</p> <p>MR jet direction</p>	<p>A1/P1 and AL commissure</p> <p>} as above</p>	
<p>Modified PLAX Away from AV</p> <p>Sweep (scout) through valve segments</p>	<p>2D</p> <p>Colour Doppler</p>	<p>Segments viewed</p> <p>Leaflet motion Leaflet thickness Calcification LV wall motion abnormalities</p> <p>MR jet direction</p>	<p>A3/P3 and PM commissure as above</p> <p>} as above</p>	

<p>PSAX, MV level</p>	<p>2D</p>	<p>Segments viewed¹</p> <p>Calcification :Annulus Ca²⁺ score :leaflets</p> <p>Annulus measurement⁴</p> <p>origin of MR jet</p> <p>subvalve calcification</p>	<p>P1,2,3 and A1,2,3 com</p> <p>Annulus scoring system⁵ (0-5: P1,P2,P3,AMVL, Commissures) As above</p> <p>commissural diameter (long axis) End systole not possible by method employed by study End diastole 37mm±4.3mm</p> <p>As above</p> <p>As above</p>	
<p>PSAX, PM level</p>	<p>Colour Doppler</p>			
<p>A4CV</p>	<p>2D</p>	<p>Segments viewed¹</p> <p>Leaflet motion</p> <p>Leaflet thickness</p> <p>Calcification</p> <p>Annulus measurement⁴</p> <p>LV wall motion abnormalities</p> <p>MR jet direction</p>	<p>A1/2 (may see A3) and P1/2</p> <p>Note: caution required not to over diagnose prolapse in this view: annular plane rises above line of normal coaptation and may give false impression of leaflet falling into LA, see reference (7)</p> <p>As above</p> <p>Oblique cut through annulus (diameter) End systole 35mm±3.1mm End diastole 30mm±2.8mm</p> <p>As above</p>	
<p>A2CV</p>	<p>2D</p>	<p>Segments viewed</p> <p>Leaflet motion</p> <p>Leaflet thickness</p> <p>Calcification</p> <p>LV wall motion abnormalities</p> <p>MR jet direction</p>	<p>A1/2(3) and P3</p> <p>} As above</p>	

A3CV	2D Colour Doppler	Segments viewed Leaflet motion Leaflet thickness Calcification LV wall motion abnormalities MR jet direction	A2 and P2 } As above	
General considerations		MR severity MR aetiology ² MR mechanism ² LV dimensions LVEF LV wall motion abnormalities LA size RV dimensions RV function PAP TR BP recorded BSA recorded TOE indication	See regurgitation quantification guidelines Where possible comment on most likely cause (eg rheumatic, degenerative, functional, ischaemic) Describe underlying mechanism of valve failure (eg restriction of P2/3 due to underlying RWMA, or P2 flail with additional P1 prolapse) See chamber quantification guidelines TAPSE, TDI severity presence, severity, aetiology (eg annulus dilatation 2o RV dilatation, 1o valve lesion include prolapse) index values as appropriate (eg LV size) question over MR severity poor imaging clarification of mechanism	

References

- (1) standard imaging planes are given below Monin JL et al JACC 2005; 46(2): 302-9
- (2) leaflet mobility: MECHANISM **‘Carpentier’s classification’** in relation to annulus plane it is helpful to think and so describe this in terms of aetiology and mechanism of valve failure
- (3) *Agricola E et al. Eur J echocardiography 2004; 5: 326-34, NB measurements from **PLAX view** **Calafiore AM et al. Ann Thorac Surg 2004; 77: 1989-97 , NB measurements from **4C view**
- (4) Nordblom P et al Echocardiography 2007; 24(7); 665-72 : 38 normals, 60% women
- (5) Louie EK et al. JACC 1996: 28(2); 465-71 NB **TOE study**
- (6) d’Alessandro C et al. Eur J Cardio-thoracic Surg 2007;32;596-603
- (7) Levine RA et al. J Am Coll Cardiol. 1988 ;11(5):1010-9